

# A deep-learning algorithm to determine liver fat content in non-alcoholic fatty liver disease in humans

## Authors:

Laura E. Ahtiainen<sup>1,2</sup>

Panu K. Luukkonen<sup>1,2</sup>

Tuomas Ropponen<sup>3</sup>

Sami Blom<sup>3</sup>

Johanna Arola<sup>1,4</sup>

Hannele Yki-Järvinen<sup>1,2</sup>

<sup>1</sup>University of Helsinki, Helsinki, Finland; <sup>2</sup>Minerva foundation institute for medical research, Helsinki, Finland; <sup>3</sup>Fimic Oy, Helsinki, Finland; HUSLAB Department of Pathology, Helsinki University hospital, Helsinki, Finland

## BACKGROUND

Non-alcoholic fatty liver disease (NAFLD) is the most common cause for chronic liver disease in the Western countries. The golden standard for diagnosis is liver biopsy which is assessed by a pathologist using the steatosis-activity-fibrosis (SAF)-score. Because the biopsies are assessed by a pathologist, the scores are subject to considerable inter-personal variation. Therefore, there is a need for new objective and automated methods for assessment of liver histology.

## SPECIFIC AIM

To determine whether liver fat content can be determined using a deep neural network algorithm.

## METHODS

### SUBJECTS

Liver biopsies from 160 subjects were examined from a cohort of patients undergoing bariatric surgery who met the following criteria: a) age 18-75 years; b) no known acute or chronic disease except for obesity, type 2 diabetes or hypertension; c) alcohol consumption less than 20 g per day for women and less than 30 g per day for men; d) no clinical or biochemical evidence of other liver disease; e) no history of use of toxins or drugs associated with liver steatosis. The mean age was  $50 \pm 1$  years and mean BMI  $42.5 \pm 0.5$  kg/m<sup>2</sup>.

### LIVER HISTOLOGY

Liver histology was determined conventionally by the same liver pathologist using the SAF-score. 29 % of the subjects had normal liver histology, 35 % had simple steatosis, 6 % had NASH (non-alcoholic steatohepatitis) and 36 % had any fibrosis. The average macrovesicular steatosis was 16.2 % according to the SAF-score.

### DEEP NEURAL NETWORK ALGORITHM

Digital whole-slide images of herovici-stained liver biopsies were acquired using a panoramic slide scanner (3DHISTECH) at 0.26  $\mu$ m/px resolution. We developed a deep neural network algorithm to quantify liver fat content in the digital liver biopsy images. The algorithm was

trained to recognize liver tissue as well as structures such as capsule, portal tracts, large vessels and any artefacts to be excluded from the fat content analysis. Next, the algorithm was trained to recognize macrovesicular lipid droplets over the area of the hepatocytes. (Figures 1AB) Furthermore, the algorithm quantifies the percentage of fat over the hepatocyte area as well as the number and size of all individual lipid droplets in each biopsy section enabling assessment of lipid droplet distribution and size (Figure 3AB) in each patient. The algorithm was trained and validated using 2.9 and 428 gigapixels of data respectively.

## RESULTS

The percentage of fat determined by the algorithm correlated highly significantly with the percentage of macrovesicular steatosis from the pathologist's score ( $r=0.94$ ,  $p<0.0001$ ). (Figure 2) The average size of the lipid droplets was  $189 \pm 8.6$   $\mu$ m<sup>2</sup> and the average count of droplets was  $132 \pm 9$  droplets per square millimeter. The algorithm also quantifies the size and number of the individual lipid droplets. (Two examples shown as histograms in figure 3.)

## CONCLUSIONS

Steatosis in human NAFLD samples can be accurately analysed using the developed algorithm. This enables a large number of tissue samples to be analysed rapidly and objectively. In addition, the deep-learning approach enables the extraction of novel parameters, such as the size and number of macrovesicular lipid droplets, which is not feasible to achieve using conventional histology assessment.

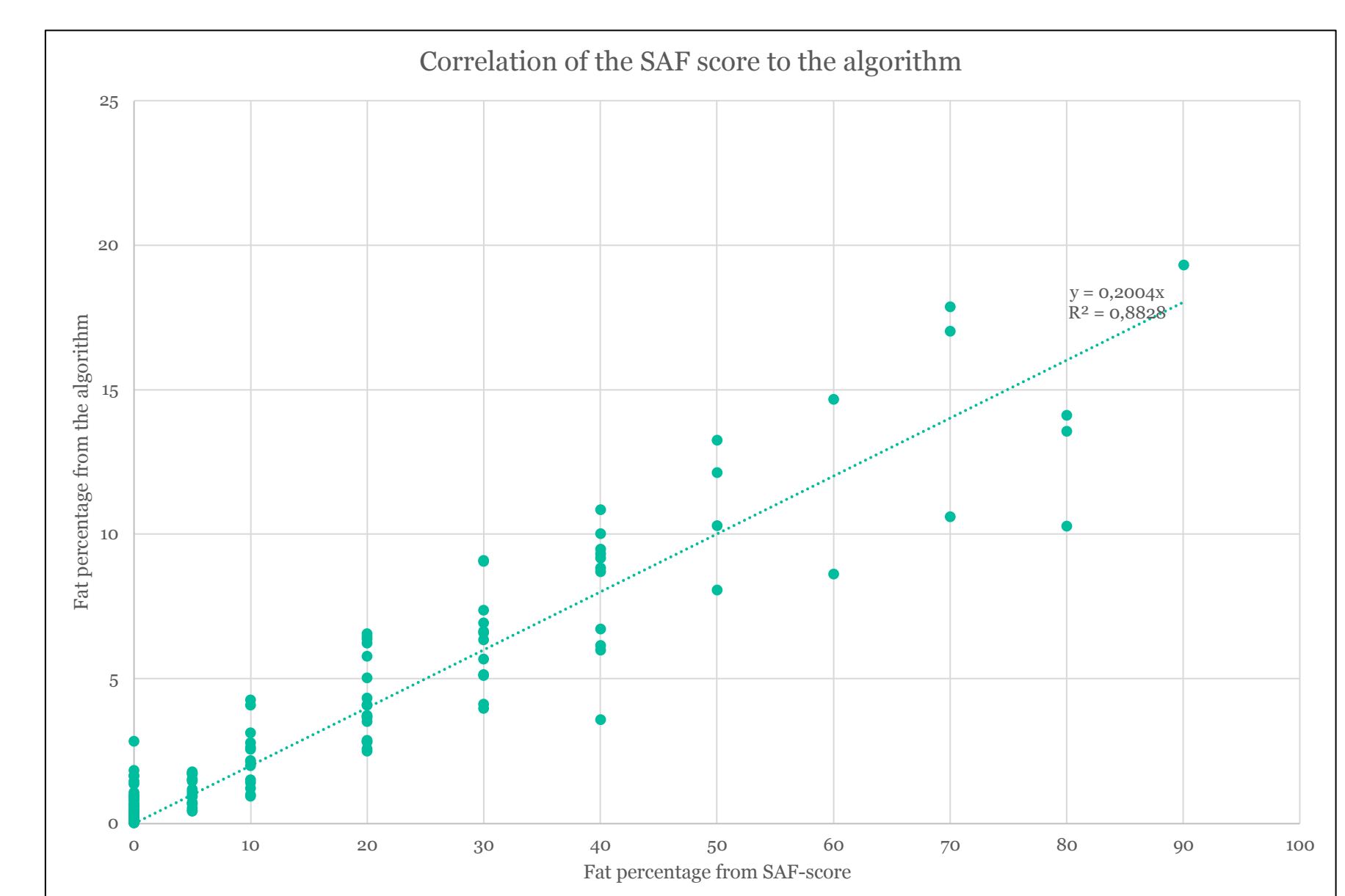


Figure 2: Correlation of the SAF-score to the algorithm.

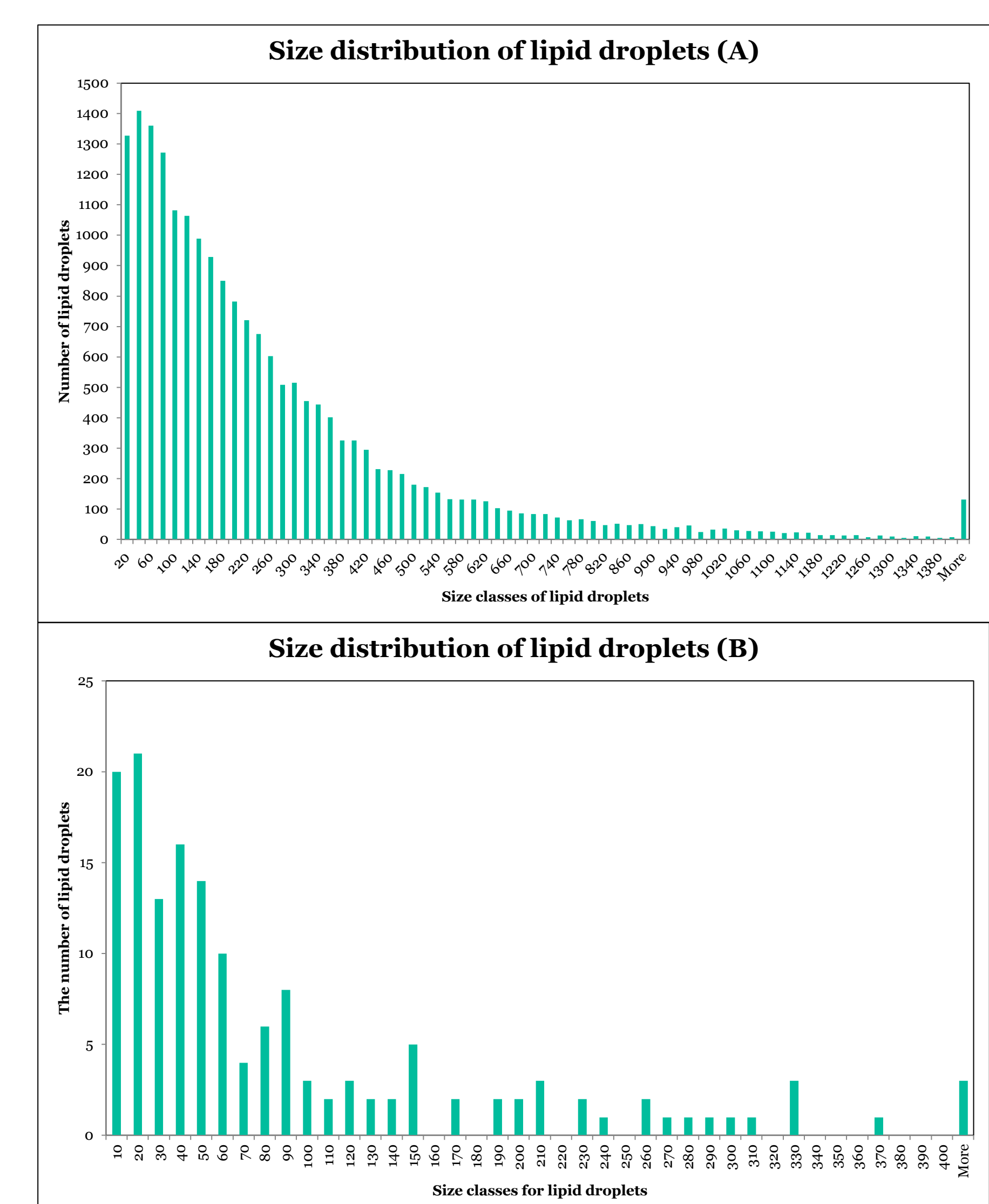


Figure 3 A and B: Two examples of histograms showing the distribution of lipid droplets according to size.

Figure 1. A: Image of a liver sample, B: Image of the same sample showing the algorithm; red marks for the area of hepatocytes and green shows the lipid droplets recognized by the algorithm.

